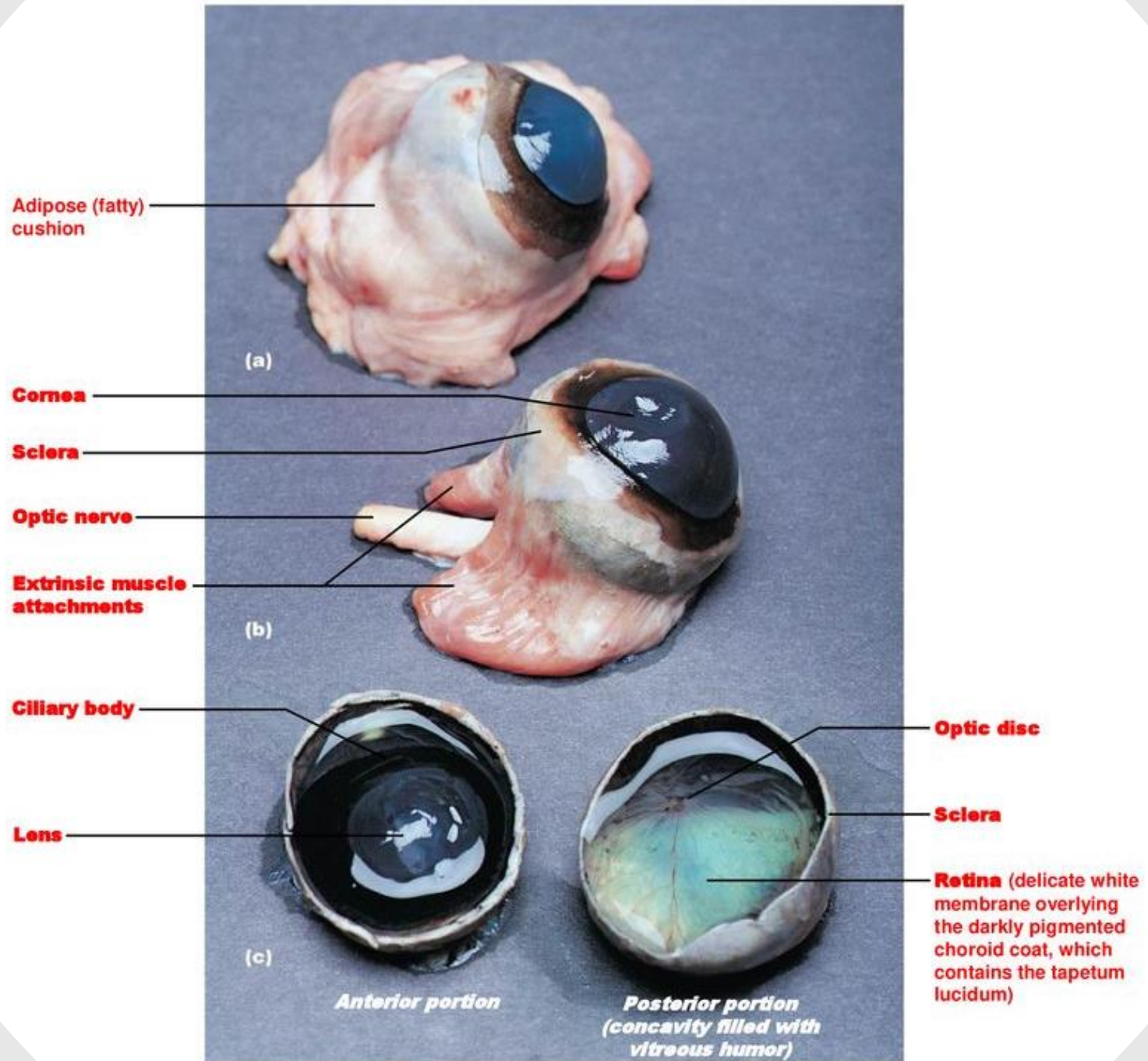
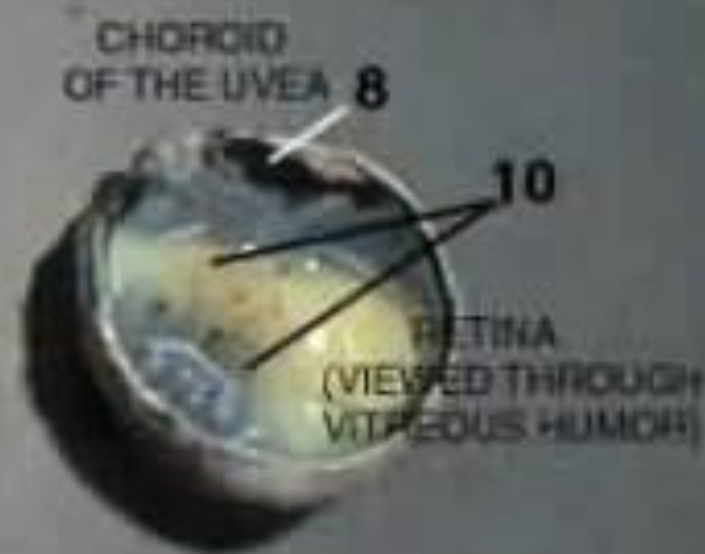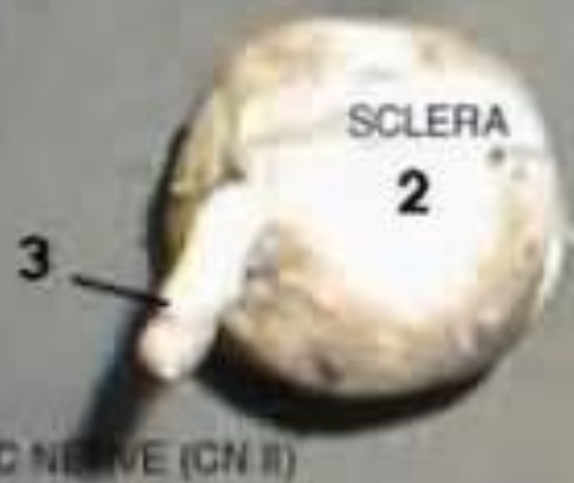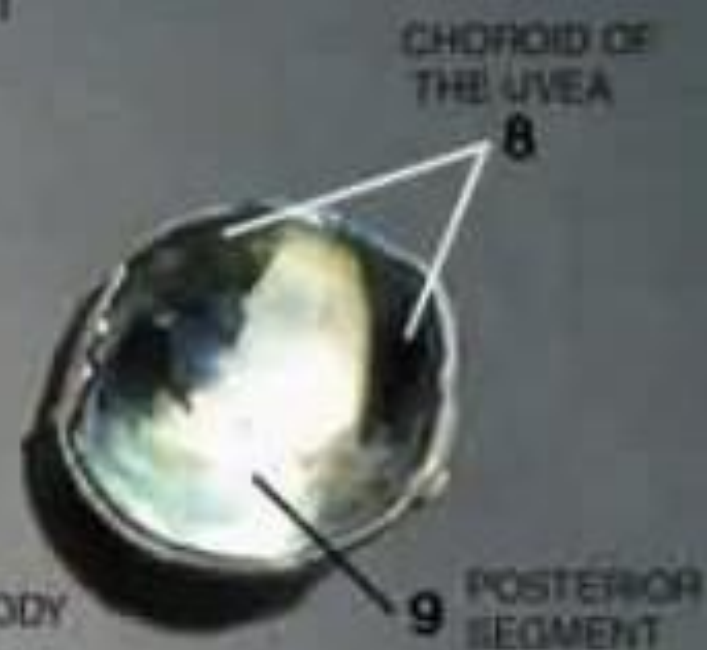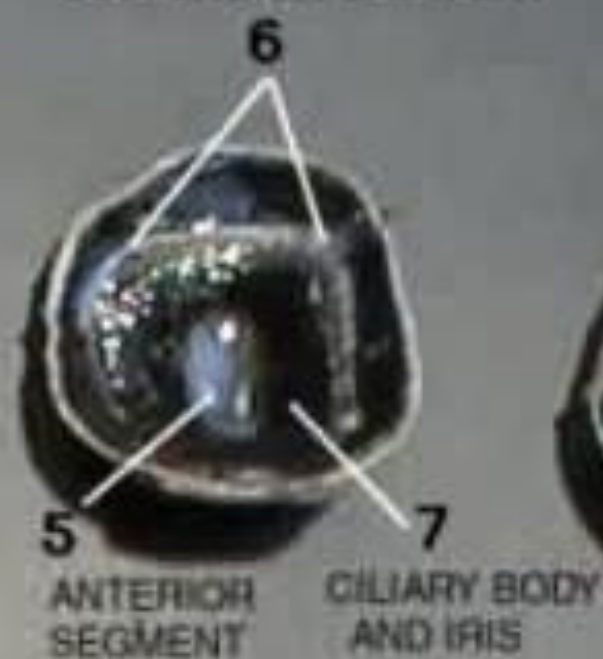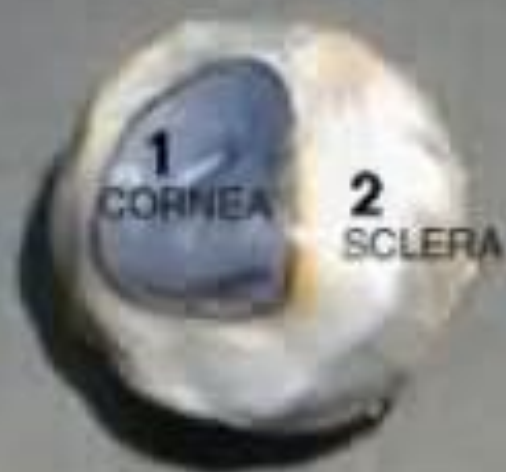
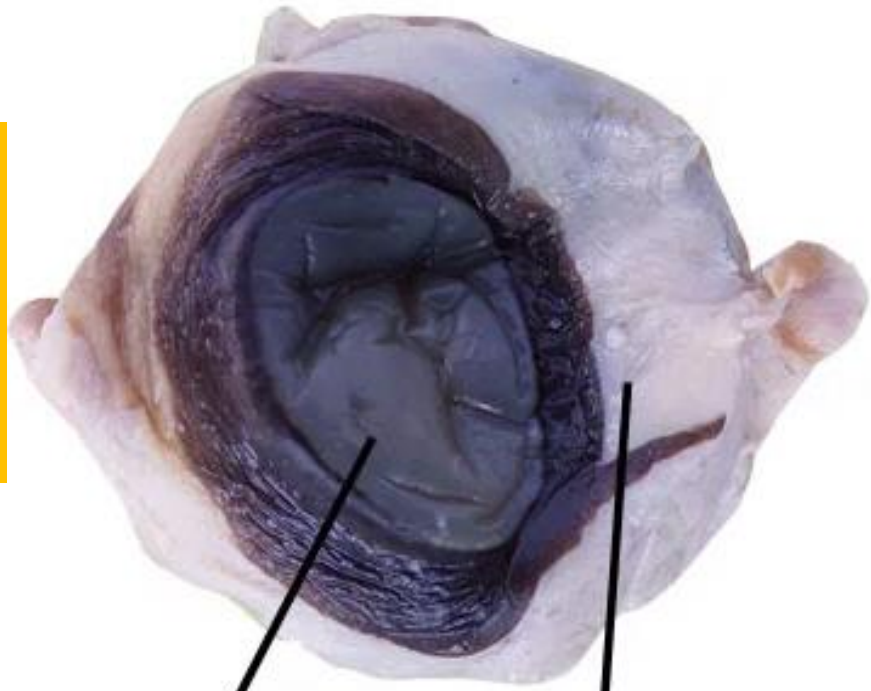


omy of the cow eye.



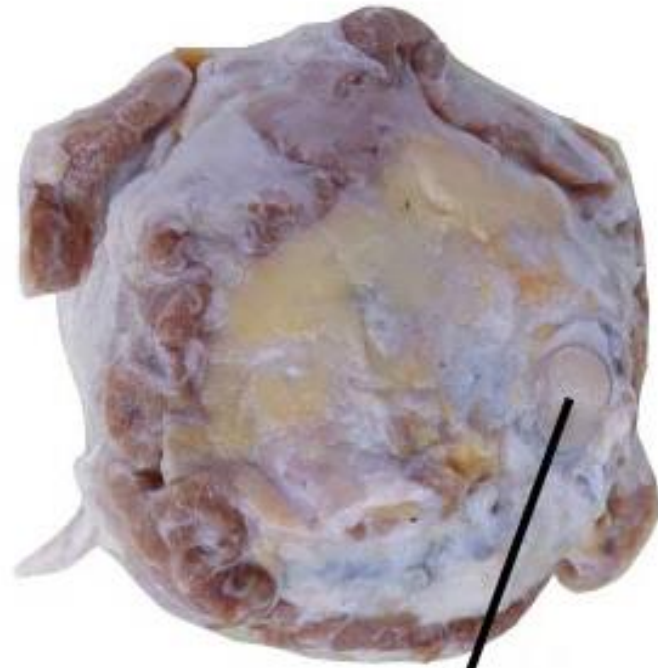

Cow eye, external surface



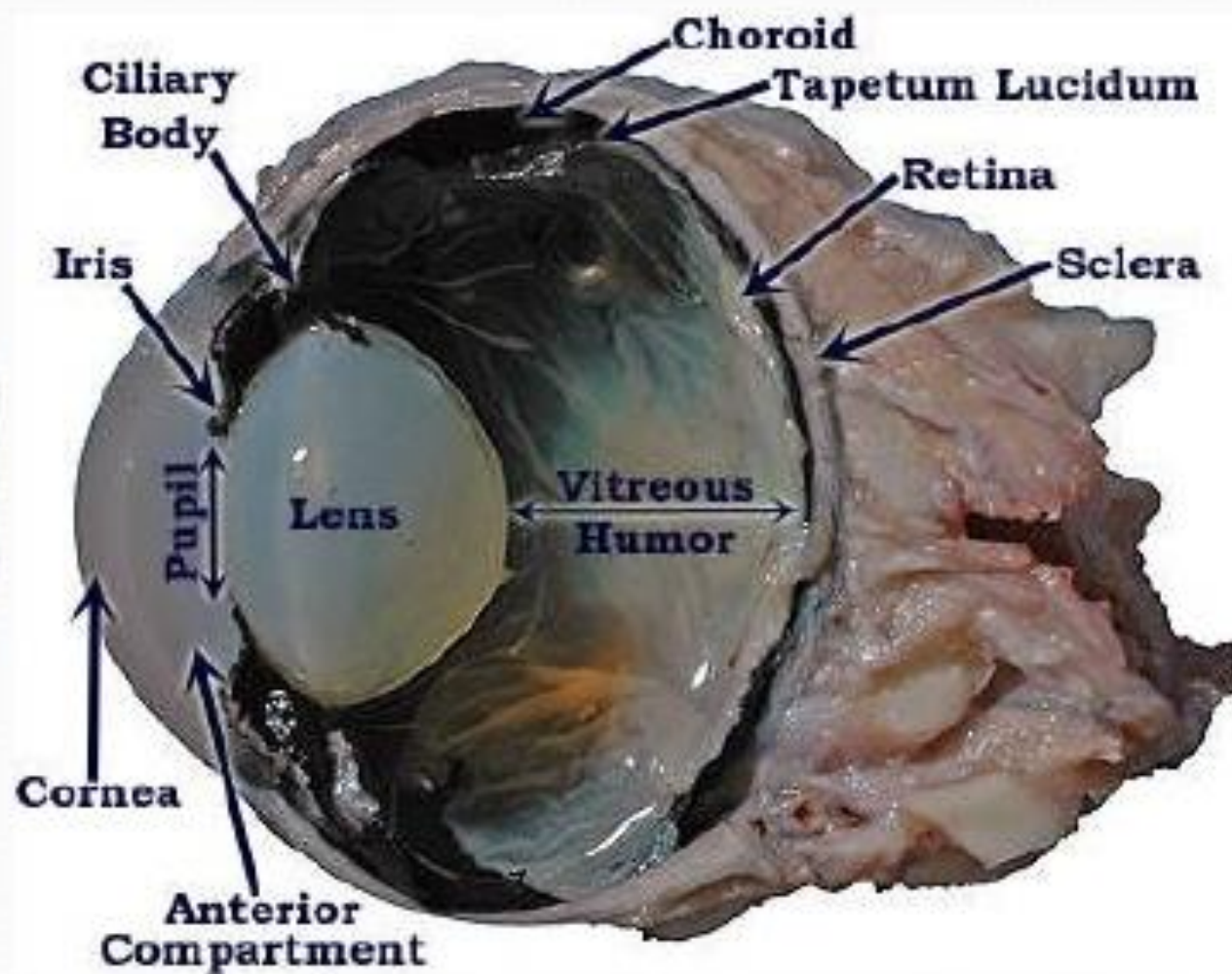
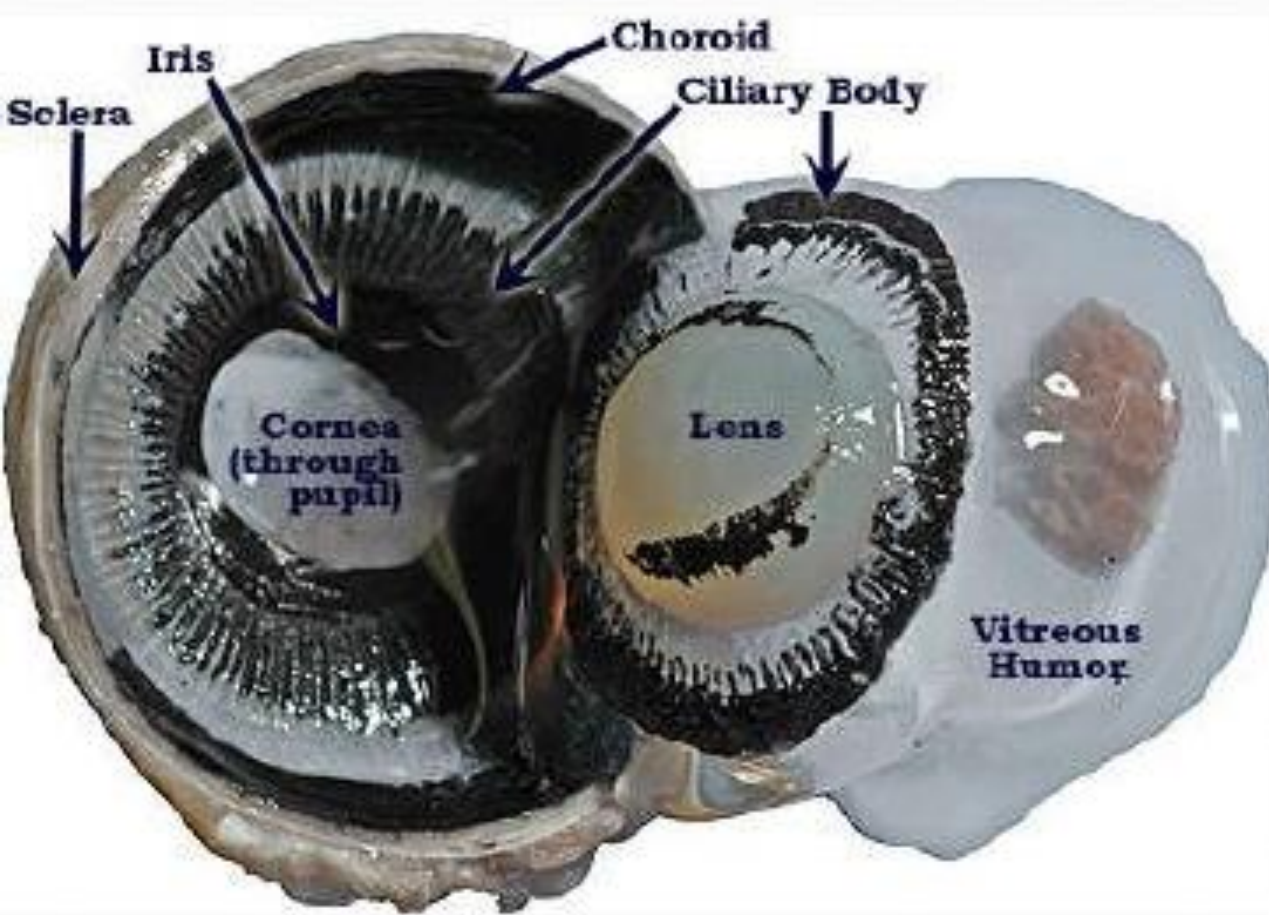
cornea

sclera

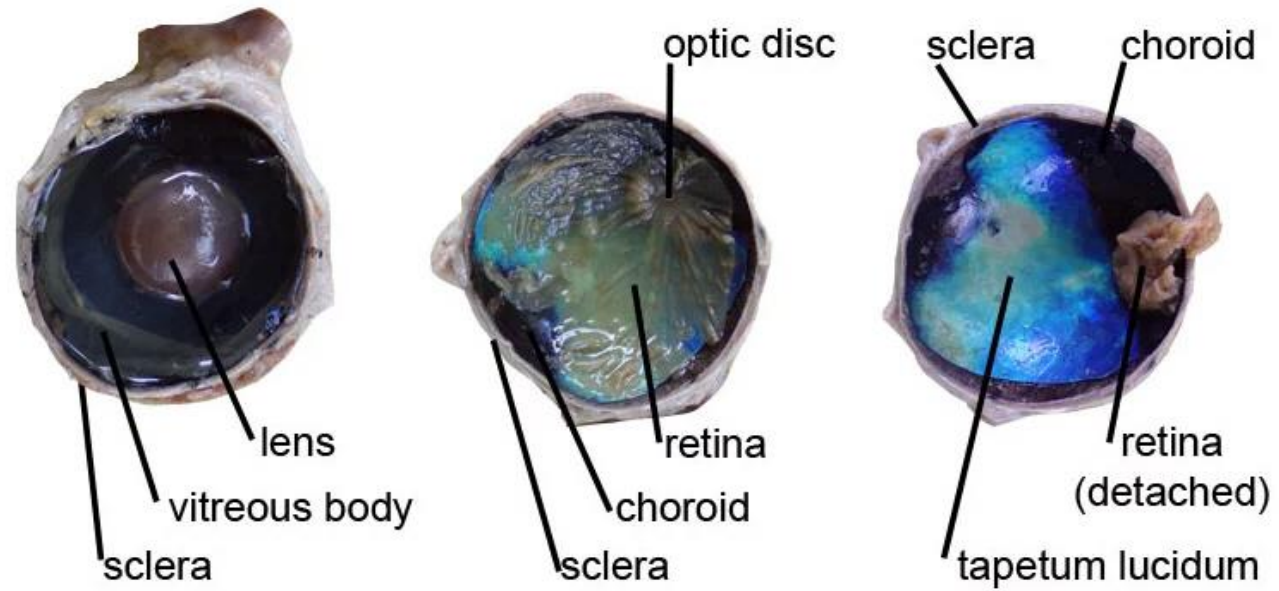


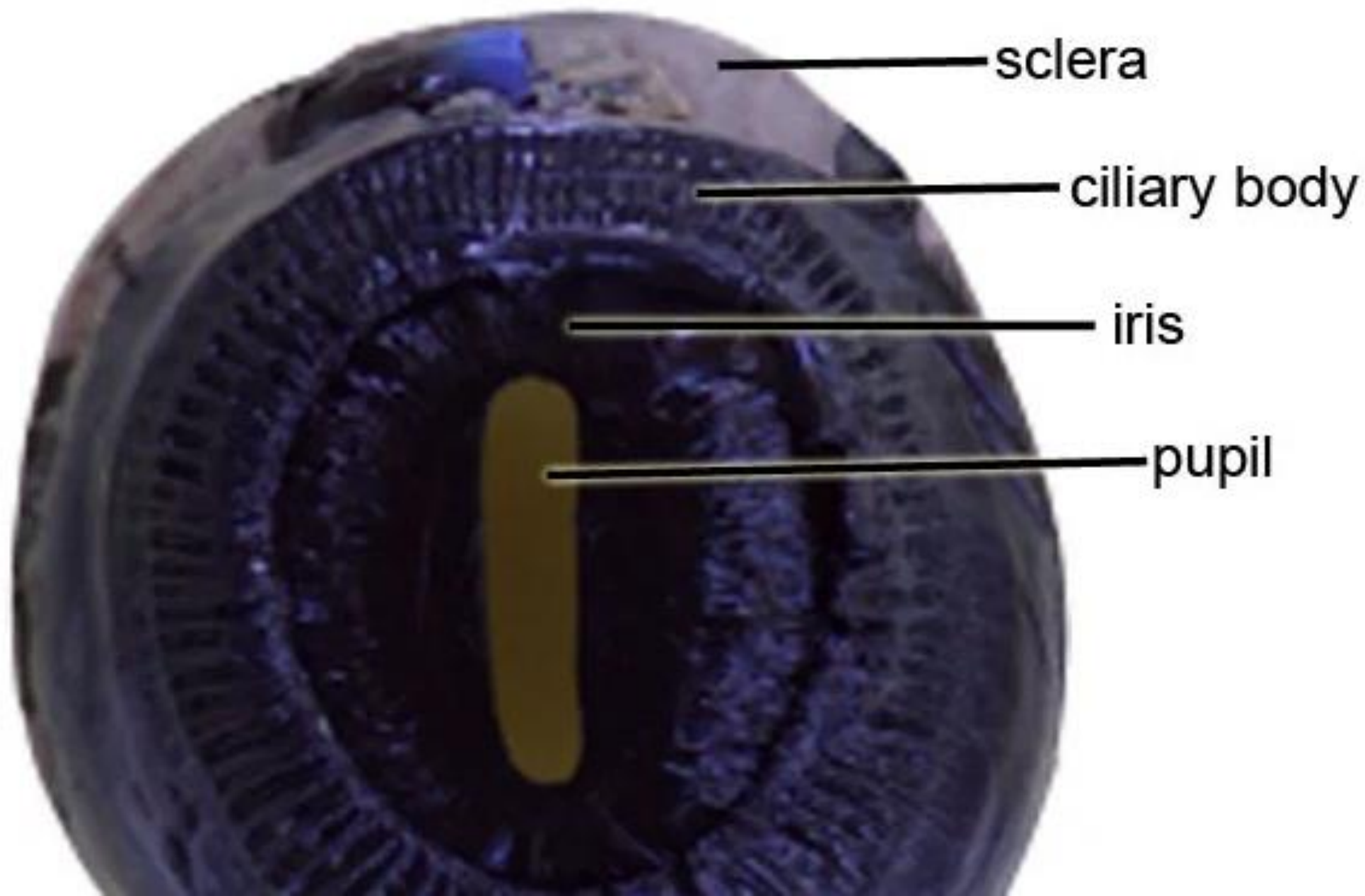
optic nerve

Cow Eye



Cow eye, posterior segment





Cow eye, anterior chamber

