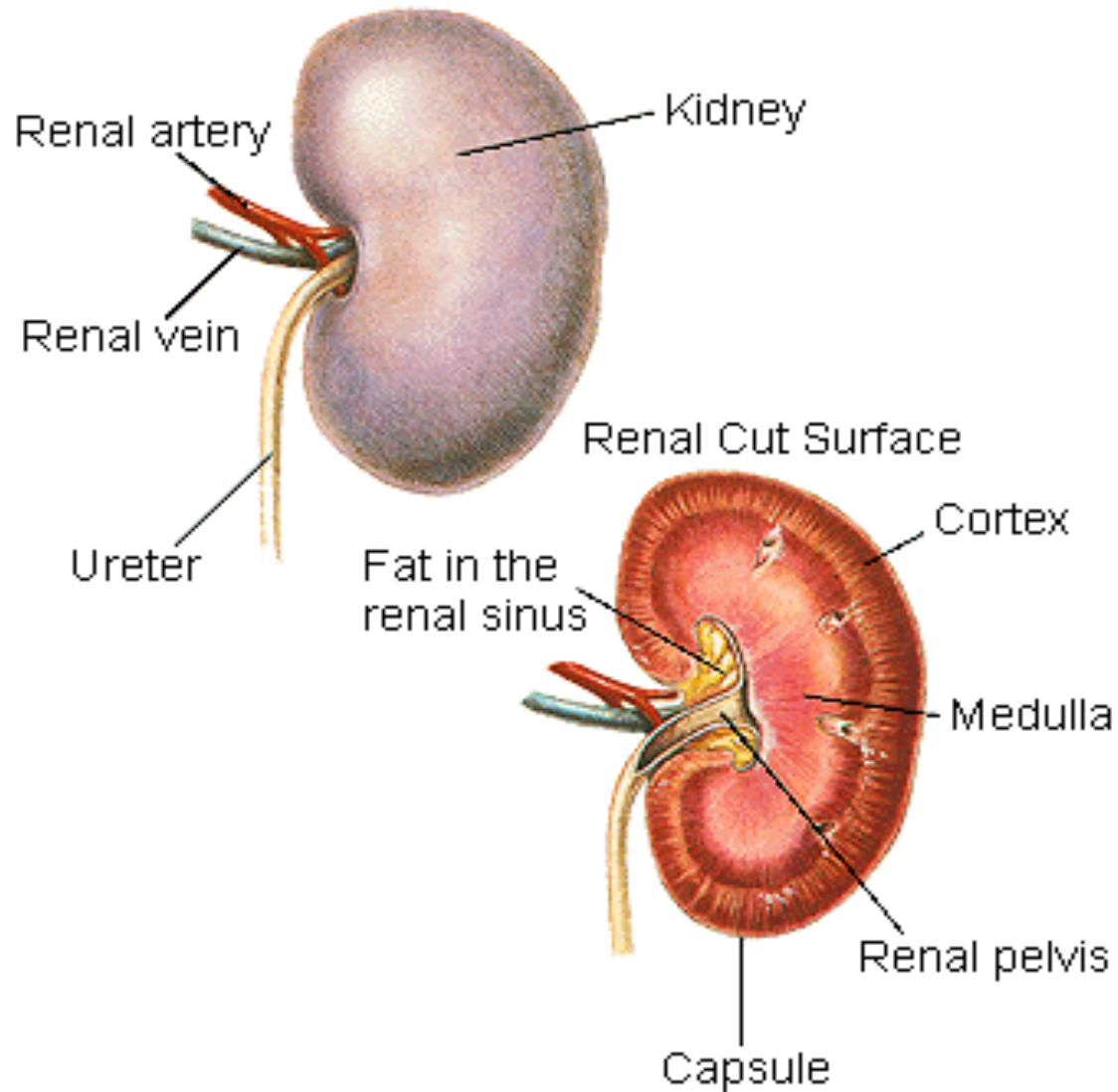


Lab 10



Cortical Column

Medullary Pyramid

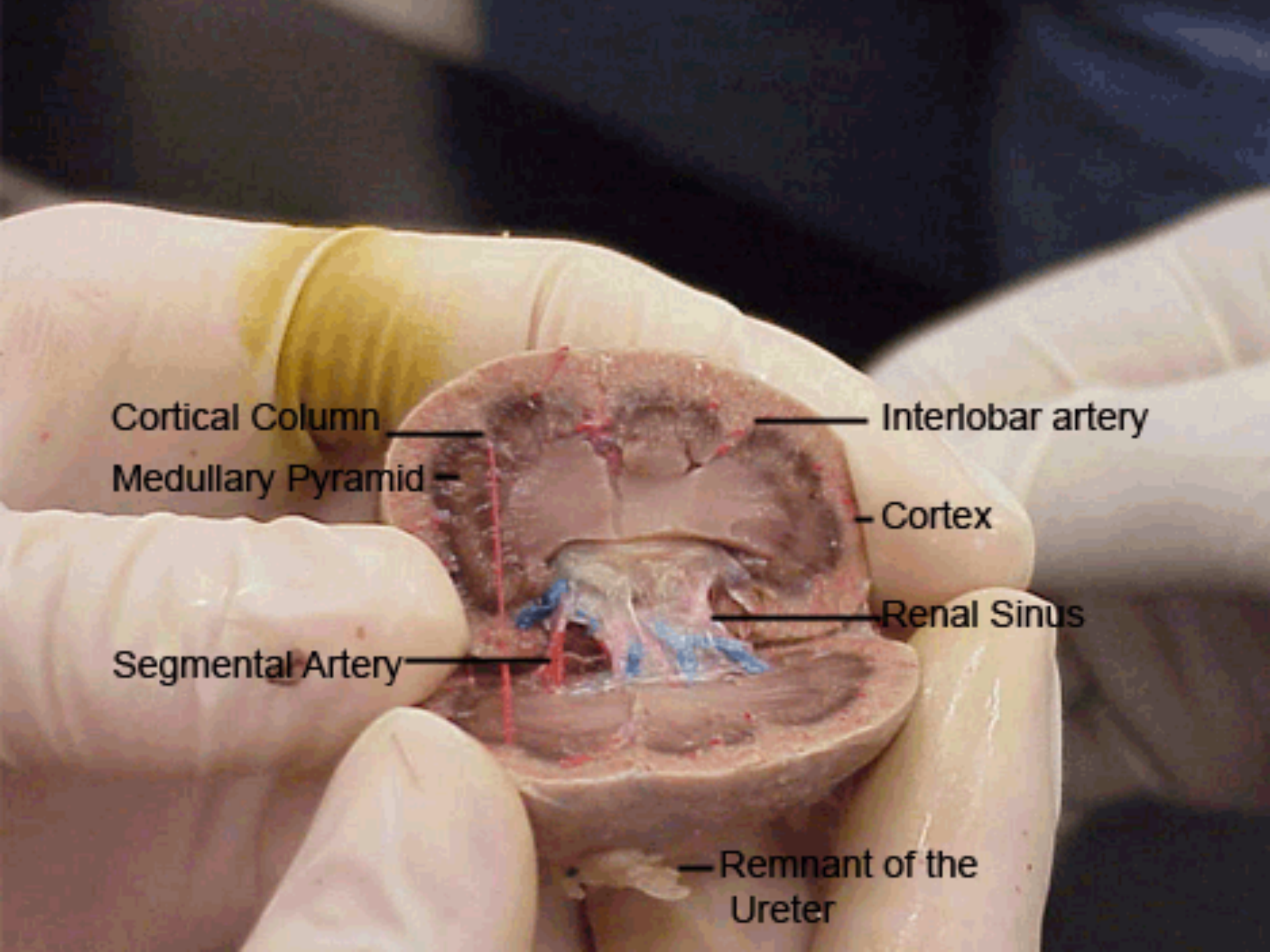
Segmental Artery

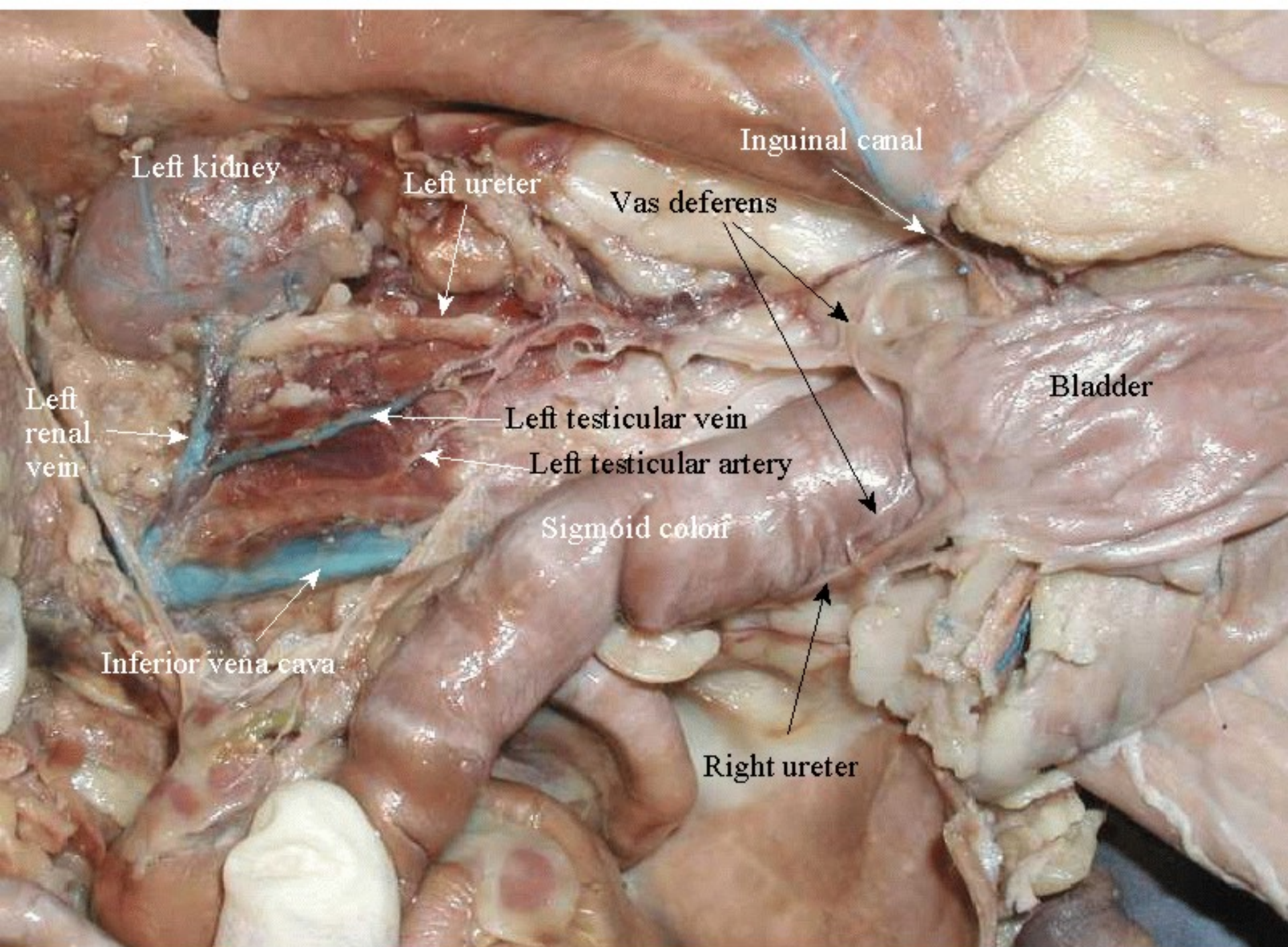
Interlobar artery

Cortex

Renal Sinus

Remnant of the Ureter





Left kidney

Left ureter

Inguinal canal

Vas deferens

Left renal vein

Left testicular vein

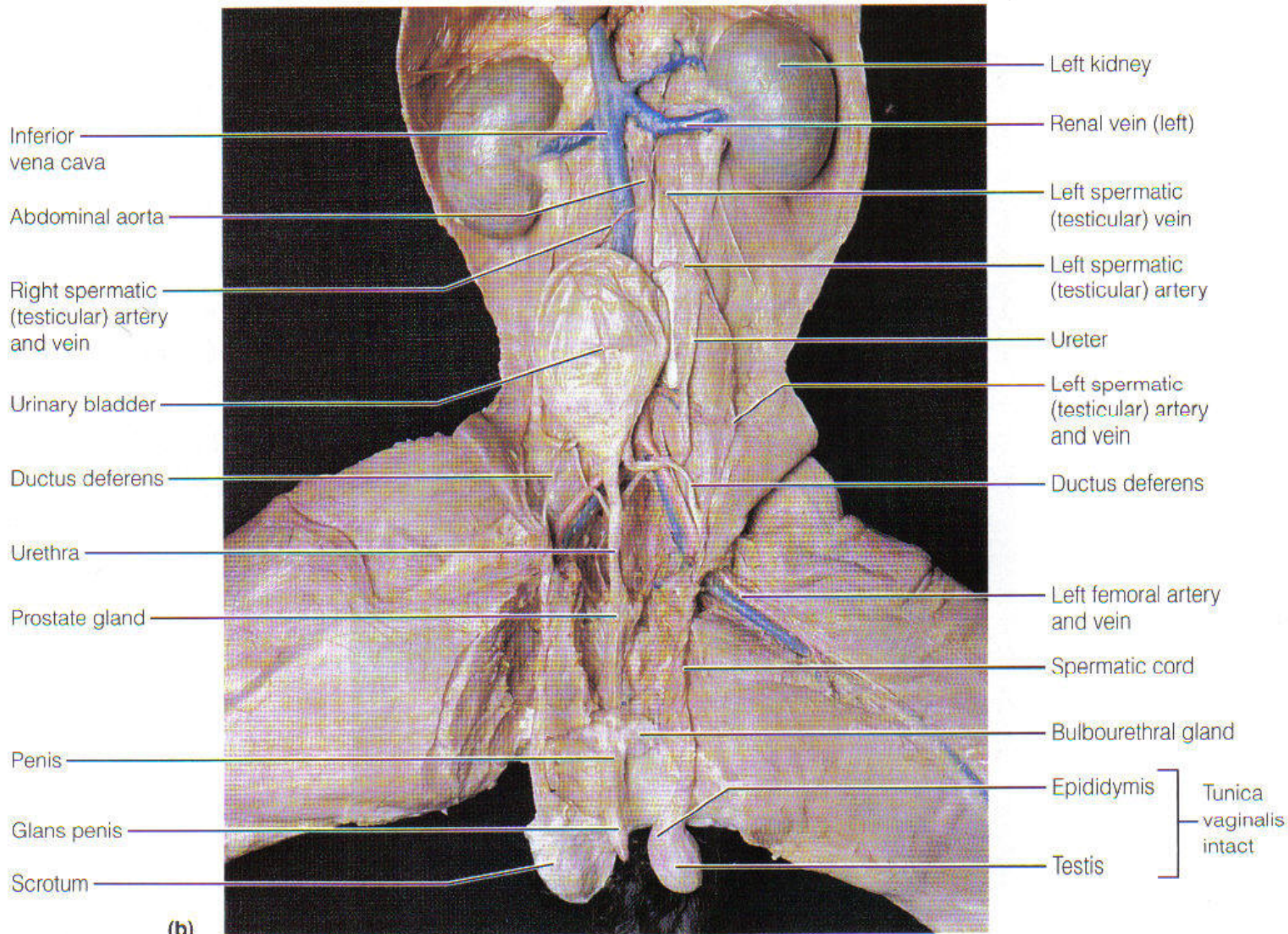
Bladder

Left testicular artery

Sigmoid colon

Inferior vena cava

Right ureter



(b)